Pakistan J. Zool., vol. 58(6), pp 2295-2307, 2026 DOI: https://dx.doi.org/10.17582/journal.pjz/20250811062324

Ascorbic Acid and Selenium Co-administration Confer Synergistic Amelioration of Cypermethrin Induced Toxicopathology in Albino Rats

Kaynaat Akbar[1,2]*, Ahmad Nawaz[2,3]*, Sajid Abdullah[1] and M. Dildar Gogi[2]

[1]*Department of Zoology, Wildlife and Fisheries, Faculty of Sciences, University of Agriculture, Faisalabad 38040, Punjab, Pakistan*
[2]*Integrated Pest Management Laboratory, Department of Entomology, University of Agriculture, Faisalabad 38040, Punjab, Pakistan*
[3]*Department of Plant Sciences, College of Agricultural and Marine Sciences, Sultan Qaboos University, Al-Khoud 123, Muscat, Oman*

Article Information
Received 11 August 2025
Revised 25 October 2025
Accepted 02 November 2025
Available online 25 May 2026 (early access)
Published 24 Septemer 2026

Authors' Contribution
KA and AN planned and designed the research experiment. KA experimented and wrote the article. SA helped with the analysis, and MDG helped with the statistical analysis. Overall, all authors read and approved the manuscript.

Key words
Toxicology, Pesticide, Antioxidants, Oxidative stress, Histopathology

ABSTRACT

Cypermethrin (CYP), a class II pyrethroid insecticide employed in domestic and agricultural pest management, was investigated for its toxicopathological effects in albino rats. This study further evaluated the individual and combined ameliorative potential of ascorbic acid (AA) and selenium (Se). Comparative biometric analysis revealed no statistically significant impact of treatments on final body weight and relative organ weights, although a trend towards reduced weight gain across treatment groups was observed. Biochemical analysis demonstrated elevated levels of hepatic aspartate aminotransferase (AST), alanine aminotransferase (ALT), and alkaline phosphatase (ALP) and lipid (Cholesterol) parameters, alongside altered antioxidant enzyme activities catalase (CAT), superoxide dismutase (SOD) and reduced glutathione (GSH) levels in the CYP-exposed group. Conversely, post-treatment with the Se+AA mixture resulted in increased GSH levels, while individual and combined antioxidant administration exhibited protective effects on AST, ALT, ALP, Cholesterol, CAT, and SOD activities. Histopathological examination of pulmonary and cerebral tissues from CYP-treated animals corroborated these biochemical alterations, revealing tissue damage including congested blood capillaries, alveolar collapse, neuronal vacuolation, necrosis, and hemorrhages, indicative of CYP-induced toxicity. In conclusion, the indiscriminate application of pesticides such as CYP presents significant health risks, and dietary supplementation with antioxidants may offer a strategy to mitigate associated toxicological burdens.

INTRODUCTION

Pesticides are widely used to control organisms that pose threats to crops, human health, and animals (Khan *et al*., 2023). However, their extensive application has led to a significant increase in pesticide-related toxicity. Globally, over three million cases of pesticide poisoning are reported annually, many of which result in fatal outcomes (Namdev *et al*., 2023). Among these, synthetic pyrethroids have emerged as a major class due to their high stability and effectiveness against agricultural pests. These compounds are synthetic analogs of naturally occurring pyrethrins found in chrysanthemum and daisy plants (Modupe *et al*., 2023). Cypermethrin (CYP), a type II synthetic pyrethroid, is frequently used in agriculture for the control of pests affecting cereals, vegetables, and fruit crops. Its mechanism involves the disruption of neuronal function by delaying the closure of voltage-gated sodium channels, thereby prolonging sodium ion influx and neuronal depolarization (Hao *et al*., 2023). At elevated exposures, this action leads to neurotoxicity, with symptoms ranging from mild sensory disturbances to severe neurological impairments.

* Corresponding author: nawazrajpoot65@gmail.com, a.nawaz1@squ.edu.om, kaynaatakbar1999@gmail.com
0030-9923/2026/0006-2295 $ 9.00/0

Copyright 2026 by the authors. Licensee Zoological Society of Pakistan.
This article is an open access article distributed under the terms and conditions of the Creative Commons Attribution (CC BY) license (https://creativecommons.org/licenses/by/4.0/).

Abbreviations
CYP, Cypermethrin; GST, Glutathione S-transferase; POD, Peroxidase; CAT, Catalase; SOD, Superoxide dismutase; AST, Aspartate aminotransferase; ALT, Alanine aminotransferase; ALP, Alkaline phosphatase; AA, Ascorbic acid; Se, Selenium; BWT, Bodyweight; ChE, Cholinesterase; H2O2, Hydrogen peroxide; R.W.T, Relative Weight; ROS, Reactive oxygen species; GSH-Px, Glutathione peroxidase; GABA, Gamma aminobutyric acid; BChE, Butyl cholinesterase.

The widespread and prolonged use of CYP increases the risk of human exposure through occupational routes (e.g., manufacturing, handling, or spraying) as well as through dietary intake from contaminated food and water sources (Abd El-Hameed and Mahmoud, 2020; Namdev *et al*., 2023). Studies have reported alarmingly high levels of CYP residues in vegetables (75.8%) and fruits (95.3%), posing a serious threat of bioaccumulation and entry into the human food chain (Tongjai *et al*., 2021). Additionally, CYP exposure has been linked to adverse gastrointestinal effects, dermal irritation, and the inhibition of butyryl cholinesterase (BChE) an enzyme crucial for normal nervous system function and a common target for insecticidal toxicity (Shilpakar and Karki, 2021; Kasuba *et al*., 2022).

Cypermethrin (CYP) readily permeates the blood-brain barrier, inducing oxidative stress and dopaminergic neurotoxicity. Its lipophilic nature contributes to a spectrum of adverse effects, including cardiotoxicity, reproductive toxicity, nephrotoxicity, hepatotoxicity, and immunotoxicity (Yuksel *et al*., 2023). A primary mechanism of neurotoxicants, including CYP, involves the disruption of antioxidant defense systems and the generation of excessive reactive oxygen species (ROS) within the brain, culminating in oxidative stress (Zuo *et al*., 2024). Oral exposure to CYP has been associated with severe cellular agglutination, hyperplasia, and pulmonary necrosis. Furthermore, CYP exposure can lead to respiratory pathologies and pulmonary edema via proteinaceous exudation, neurological damage characterized by glial cell proliferation in the brain, as well as hepatic tissue disorganization, including sinusoidal dilation and hepatocellular necrosis (Arafa *et al*., 2015; Kuban and Daniel, 2021).

Vitamins enhance enzymatic activities, gene expression and neurological functions (Oladele *et al*., 2020). Therefore, they may be able to restore implications caused by xenobiotics (Matić *et al*., 2021). Vitamin C is well well-known powerful antioxidant that can protect the body against damage caused by free radicals during normal metabolism and exposure to toxins and carcinogens (Doseděl *et al*., 2021). According to Erkan *et al*. (2021) Vitamin C (ascorbic acid) is a hydrophilic antioxidant that can reduce oxidative stress and environmental toxins. By protecting cells from free radicals, vitamin C can be used as an antioxidant to reduce oxidative stress in cells. Additionally, it prevents per-oxidative damage to the bio membrane and free radical scavengers from quenching the aqueous phase of free radicals in extracellular fluids (Ziada *et al*., 2020).

Selenium (Se), a potent antioxidant, is an essential micronutrient integral to the function of glutathione peroxidase (GSH-Px) and seleno-protein P. These enzymes play a crucial role in scavenging reactive oxygen species (ROS), thereby protecting cellular membrane lipids and macromolecules from oxidative damage (Oda and El-Maddawy, 2012). Beyond its direct antioxidant properties, Se has been shown to modulate neurotransmitter systems by increasing gamma-aminobutyric acid (GABA) and glutathione levels, and to exert anti-inflammatory effects by significantly reducing the levels of malondialdehyde (MDA), tumor necrosis factor-alpha (TNF-α), and interleukin-1 beta (IL-1β) (Baghcheghi *et al*., 2024). As a catalytic component, Se forms the active site of approximately 20 eukaryotic selenoproteins, many of which possess redox regulating, primarily antioxidant, activities. Notably, Se, through its incorporation into these selenoproteins, may also function as a chemoprotective agent and participate in metabolic processes critical for maintaining the body's defense mechanisms and overall integrity (Rashid *et al*., 2023).

The present study revealed the CYP-induced histopathological and biochemical alterations in the brain and lungs of adult albino rats and synergistic ameliorative potential of ascorbic acid and selenium against CYP -mediated toxicity.

MATERIALS AND METHODS

This research was executed in adherence to the ethical guidelines established by the institutional bioethics committee (IBC) of the University of Agriculture, Faisalabad, Pakistan (Ethical approval code: D.No.3741/ ORIC UAF, dated December 12, 2023). The experimental procedures were carried out at the animal housing facility within the Department of Clinical Medicine and Surgery, Faculty of Veterinary Sciences, University of Agriculture, Faisalabad, Pakistan. Forty adult male and female albino rats, aged 90 ± 10 days and weighing 110-145g, were utilized in this study. The assessment of cypermethrin toxicity in these animals was conducted under controlled laboratory conditions, maintaining a 12:12 h light-dark cycle at a constant temperature of 25°C.

Chemicals

The study utilized cypermethrin (100 g/L EC, manufacturer unspecified), ascorbic acid (Sigma-Aldrich), and selenium (Sigma-Aldrich) as active compounds. The dose of cypermethrin was selected based on previously published studies with slight modifications (Joshi *et al*., 2011; Sangha *et al*., 2013; Shuklan *et al*., 2023). Cypermethrin was administered at a dosage of 30 mg/kg body weight (equivalent to 1/8th of the reported LD_{50}) and ascorbic acid at 20 mg/kg body weight, both formulated in

corn oil. Selenium was dissolved in water and administered at a concentration of 0.2 mg/kg body weight.

Experimental design

Forty albino rats were stratified by body weight and randomly assigned to five experimental groups (n = 8 per group, comprising 4 males and 4 females each). Initial body weights were recorded for all subjects. Group I (negative control) received only corn oil. Group II (positive control) was administered CYP at a dosage of 30 mg/kg body weight daily for five consecutive days. Groups III, IV, and V were initially treated with CYP (30 mg/kg body weight daily for five days) followed by a three-day post-treatment with ascorbic acid (20 mg/kg body weight), selenium (0.2 mg/kg body weight), and a combination of ascorbic acid and selenium (20 mg/kg + 0.2 mg/kg body weight), respectively. No mortality was observed across any experimental group. After the treatment periods (day 5 for Groups I and II; day 8 for Groups III, IV, and V), final body weights were recorded after 8 days for each group. Subsequently, the animals were anesthetized via chloroform inhalation and subjected to necropsy. Cardiac puncture was performed to collect 3 ml of blood into gel separator tubes, which were then maintained at 25°C for 1 h to facilitate serum separation. Serum samples were carefully aliquoted into labeled Eppendorf tubes and stored at -20°C pending biochemical analysis (Ziada *et al*., 2020).

Histopathological studies

Following necropsy, lung and brain tissues were excised from the albino rat specimens and immediately fixed in 10% neutral buffered formalin. These tissues were subsequently processed for histopathological analysis according to the methodology outlined by Bancroft and Gamble (2008). Morphological alterations within the tissue architecture were then assessed via light microscopy (HD 1500 T, Meiji Techno, Japan) (Shuklan *et al*., 2023).

Serum analysis

Serum levels of alanine transaminase (ALT), aspartate transaminase (AST), alkaline phosphatase (ALP), cholesterol, creatinine and uric acid were determined using commercially available assay kits (alanine assay kit catalogue MAKOO1, AST assay activity kit catalogue MAKO55, ALP activity kit AP0100, creatinine assay kit (Gunduz *et al*., 2021).

Oxidative stress

Assessment of oxidative stress markers was performed using commercially available kits from Sigma-Aldrich to quantify the concentrations of superoxide dismutase (SOD) (CS0009), peroxidase (POD) (MAK092), catalase (CAT) (CAT100), and reduced glutathione (GSH) (MAK437), following the manufacturer's protocols.

Statistical analysis

The collected data was subjected to statistical analysis employing a one-way analysis of variance (ANOVA) based on a completely randomized design. Significant differences between the control and treatment groups were determined at a probability level of $p < 0.05$ using the Minitab statistical software package.

RESULTS

Body and organ weight

Comparative biometric analysis in female albino rats revealed a statistically non-significant effect of the applied treatments on final body weight and relative body weight, although a trend towards reduced weight was observed across all treatment groups compared to the control. A significant reduction in absolute brain weight was evident in female rats treated with CYP+AA (1.25 ± 0.026 g), CYP+Se (0.89 ± 0.137 g), and CYP+AA+Se (0.75 ± 0.14 g) compared to the control group (1.56 ± 0.098 g). Conversely, no significant difference in absolute brain weight was observed between the CYP-treated female rats and the control group. Analysis of relative brain weight indicated significantly higher values in the CYP (0.95 ± 0.02) and CYP+AA (0.83 ± 0.03) treated female rats, while CYP+Se (0.78 ± 0.07) and CYP+AA+Se (0.92 ± 0.19) treated females showed no significant variation compared to the control group (0.90 ± 0.04). Absolute lung weight remained statistically unaffected by all treatments, except for the CYP+AA+Se combination (0.68 ± 0.089 g), which exhibited a significant decrease. Mean comparison of relative lung weight demonstrated no significant impact of individual CYP (0.80 ± 0.071) and CYP+AA (0.83 ± 0.109) treatments compared to the control (0.83 ± 0.019). However, post-treatment with Se (0.78 ± 0.06) and AA+Se (0.77 ± 0.17) following CYP exposure resulted in a significant reduction in relative lung weight compared to the control group (Table I).

Comparative biometric analysis in male albino rats also demonstrated a statistically non-significant effect of the applied treatments on final body weight and relative body weight, although a trend towards reduced weight was observed across all treatment groups compared to the control. A significant increase in absolute brain weight was evident in male rats treated with CYP+AA+Se (1.69 ± 0.034 g), while a significant reduction was observed in the CYP+Se treated group (1.49 ± 0.078 g) compared to the control group (1.57 ± 0.02 g). Conversely, no significant

alteration in absolute brain weight was observed between the CYP-treated male rats and the control group. Analysis of relative brain weight indicated a significant reduction in the CYP+Se (0.88 ± 0.09) and CYP+AA+Se (0.94 ± 0.02) treated male rats, while CYP (1.13 ± 0.26) and CYP+AA (1.08 ± 0.18) treated males showed no significant variation compared to the control group (1.01 ± 0.02). A significant increase in absolute lung weight was observed in the CYP+AA (1.79 ± 0.09 g) and CYP+AA+Se (1.50 ± 0.10 g) treated male rats, while CYP (1.41 ± 0.11 g) and CYP+AA (1.07 ± 0.04 g) treatments showed no significant difference compared to the control (1.11 ± 0.15 g). Relative lung weight remained statistically unaffected by all treatments in male rats (Table I).

Biochemical alterations

Biochemical analysis in female albino rats revealed a significant elevation in serum AST, ALP, ALT, and cholesterol levels in the CYP-treated group when compared to the control group. Post-treatment with CYP+AA, CYP+Se, and CYP+AA+Se resulted in a significant reduction in AST (85.90 U/L, 85.90 U/L, 78.25 U/L), ALP (57.22 U/L, 59.51 U/L, 52.64 U/L), ALT (55.30 U/L, 56.48 U/L, 47.66 U/L), and cholesterol (82.58 mg/dL, 83.33 mg/dL, 74.62 mg/dL) levels compared to the CYP-treated group (AST: 104.14 U/L; ALP: 73.24 U/L; ALT: 77.07 U/L; Cholesterol: 92.93 mg/dL) (Table II). The CYP-treated group also exhibited significantly elevated levels of creatinine (0.86 mg/dL), and uric acid (20.86 mg/dL) compared to the control group (creatinine: 0.49 mg/dL; uric acid: 5.39 mg/dL). Post-treatment with CYP+AA, CYP+Se, and CYP+AA+Se led to a reduction in creatinine levels to 0.74 mg/dL, 0.73 mg/dL, and 0.64 mg/dL, respectively, when compared to the CYP-treated group (Table II).

Biochemical analysis in male albino rats also revealed a significant elevation in serum AST, ALP, ALT, and cholesterol levels in the CYP-treated group when compared to the control group. Post-treatment with CYP+AA, CYP+Se, and CYP+AA+Se resulted in a significant reduction in AST (87.07 U/L, 85.90 U/L, 72.37 U/L), ALP (53.78 U/L, 64.08 U/L, 45.77 U/L), ALT (54.72 U/L, 54.13 U/L, 41.77 U/L), and cholesterol (82.70 mg/dL, 81.82 mg/dL, 73.11 mg/dL) levels compared to

Table I. Effect of cypermethrin (CYP), ascorbic acid (AA), and selenium (Se), administered alone or in different combinations on absolute and relative body, brain, and lung weights in adult albino rats. Significant reductions in brain weight were observed in CYP-treated females, CYP+Se, and CYP+AA+Se groups compared to controls. The female relative brain weights were significantly lower in CYP+Se than in CYP, while relative brain weights of males were significantly reduced in CYP+Se and CYP+AA+Se compared to CYP alone. Female lung weights were significantly reduced in CYP+AA+Se than in the control.

Parameters	Control	CYP	CYP+AA	CYP+Se	CYP+AA+ Se
Female rats					
Initial weight (mg/kg)	126.29±0.87^{a}	134.17±3.01^{a}	126.57±21.29^{a}	151.98±4.09^{a}	133.04±0.79^{a}
Final weight (mg/kg)	151.64±11.02^{a}	145.26±0.63^{a}	142.16±17.69^{a}	167.55±0.89^{a}	148.97±3.25^{a}
Weight gain (g)	25.36±10.95^{a}	11.09±2.47^{a}	13.59±5.07^{a}	15.56±3.70^{a}	15.93±2.55^{a}
Brain Wt.(g)	1.56±0.09^{8}a	1.38±0.04^{ab}	1.25± 0.02^{6}b	0.89±0.13^{7}c	0.75±0.1^{4}c
Lungs Wt.(g)	1.18± 0.14^{a}	1.175±0.09^{a}	1.26± 0.16^{a}	0.77±0.11^{ab}	0.68±0.08^{9}b
Brain relative Wt. (%)	0.90±0.0^{4}b	0.95±0.0^{2}a	0.83± 0.0^{3}a	0.78± 0.0^{7}b	0.92± 0.1^{9}b
Lungs relative Wt. (%)	0.83± 0.01^{9}a	0.80±0.07^{1}a	0.83± 0.10^{9}a	0.78±0.0^{6}b	0.77± 0.17^{0}b
Male rats					
Initial weight (mg/kg)	112.80±5.53^{a}	138.76± 2.08^{a}	128.52± 1.73^{a}	151.25± 21.37^{a}	194.67± 0.97^{a}
Final weight (mg/kg)	147.96±3.27$_{a}$	159.74± 6.48^{a}	155.47±5.86^{a}	179.31±32.63^{a}	206.41± 2.02^{a}
Weight gain (g)	35.15±7.97^{a}	20.98± 4.85^{a}	26.95± 5.11^{a}	28.06±11.26^{a}	11.74± 1.24^{a}
Brain (g)	1.57± 0.02^{bc}	1.64±0.02^{ab}	1.52±0.01^{b}	1.49±0.078^{c}	1.69± 0.034^{a}
Lung's weight (g)	1.11± 0.15^{c}	1.41±0.11^{bc}	1.07±0.04^{c}	1.79±0.09^{a}	1.50± 0.10^{ab}
Brain relative Wt. (%)	1.01± 0.02^{a}	1.13± 0.26^{a}	1.08± 0.18^{a}	0.88± 0.09^{b}	0.94±0.02^{b}
Lungs relative Wt. (%)	0.74± 0.05^{a}	0.97± 0.24^{a}	0.79± 0.11^{a}	1.07± 0.12^{a}	1.01± 0.04^{a}

*Means that do not share a letter are significantly different.

Table II. Effect of cypermethrin (CYP), ascorbic acid (AA), and selenium (Se), administered alone or in different combinations on oxidative stress parameters in albino rats. CYP significantly elevated all parameters compared to controls in both sexes. Co-treatment with AA or Se significantly reduced enzyme and cholesterol levels, though values often remained elevated relative to controls. Combined AA and Se co-treatment led to further reductions, with AST, ALT, cholesterol and creatinine in males and uric acid in females approaching or reaching non-significant differences from control levels.

	Parameter	Control	CYP	CYP+AA	CYP+Se	CYP+AA+ Se
Male	AST (U/l)	63.54±1.02 ^{d}	108.25±0.59 ^{a}	87.07±0.59 ^{b}	85.90±1.18 ^{b}	72.37±1.02 ^{c}
	ALT (U/l)	32.95±0.59 ^{d}	67.66±0.59 ^{a}	54.72±1.02 ^{b}	54.13±0.59 ^{b}	41.77±0.59 ^{c}
	ALP (U/l)	32.04±1.14 ^{e}	77.81±1.14 ^{a}	53.78±1.14 ^{c}	64.08±1.14 ^{b}	45.77±1.14 ^{d}
	Cholesterol (mg/dl)	59.60±0.67 ^{d}	92.17±1.10 ^{a}	82.70±0.55 ^{b}	81.82±1.33 ^{b}	73.11±1.00 ^{c}
	Uric acid (mg/dl)	3.46±0.76^{d}	19.64±0.23^{a}	12.57±0.26^{b}	11.58±0.69^{b}	8.34±0.20^{c}
	Creatinine (mg/dl)	0.52±0.01^{c}	0.86±0.02^{a}	0.71±0.01^{b}	0.74±0.01^{b}	0.60±0.01^{c}
Female	AST (U/l)	61.19±0.59 ^{d}	104.14±1.02 ^{a}	85.90±0.59 ^{b}	85.90±1.18 ^{b}	78.25±0.59 ^{c}
	ALT (U/l)	35.89±0.59 ^{d}	77.07±1.18 ^{a}	55.30±1.18 ^{b}	56.48±1.02 ^{b}	47.66±1.02 ^{c}
	ALP (U/l)	35.47±1.14 ^{d}	73.24±1.14 ^{a}	57.22±1.14 ^{bc}	59.51±1.14 ^{b}	52.64±1.14 ^{c}
	Cholesterol (mg/dl)	67.42±0.58 ^{d}	92.93±1.10 ^{a}	82.58±0.79 ^{b}	83.33±0.22 ^{b}	74.62±0.44 ^{c}
	Uric acid (mg/dl)	5.39±0.69^{a}	20.86±0.63^{a}	11.69±1.08^{b}	11.18±0.59^{c}	7.90±0.35^{d}
	Creatinine (mg/dl)	0.49±0.66^{d}	0.86±0.02^{a}	0.74±0.00^{b}	0.73±0.01^{bc}	0.64±0.01^{c}

*Means that do not share a letter are significantly different.

Table III. Effect of cypermethrin (CYP), ascorbic acid (AA), and selenium (Se), administered alone or in combination on the oxidative stress parameters in albino rats. CYP significantly decreased all oxidative stress markers compared to controls. Co-treatment with Vit C or Se partially restored enzyme activities and GSH levels, while combined Vit C+Se administration led to near-complete normalization, with most parameters showing non-significant differences from controls.

	Treatment	Control	CYP	CYP+Vit C	CYP+ Se	CYP+Vit C+Se
Male	CAT (U/min)	2.72±0.02^{a}	1.83±0.09^{c}	2.10±0.03^{b}	2.33±0.03^{b}	2.64±0.01^{a}
	SOD (U/min)	6.91±0.09^{a}	3.75±0.06^{c}	4.17±0.02^{b}	4.38±0.07^{b}	6.87±0.07^{a}
	POD (U/min)	10.8±0.16^{a}	7.40±0.26^{d}	8.18±0.02^{c}	8.43±0.03^{c}	9.43±0.05^{b}
	GSH (mg/dl)	6.89±0.13^{a}	3.08±0.03^{c}	4.17±0.01^{b}	4.51±0.02^{b}	6.71±0.17^{a}
Female	CAT (U/min)	2.75±0.03^{a}	1.83±0.04^{c}	2.13±0.02^{b}	2.22±0.05^{b}	2.68±0.02^{a}
	SOD (U/min)	6.86±0.11^{a}	3.70±0.05^{d}	4.16±0.02^{c}	4.41±0.04^{c}	6.36±0.05^{b}
	POD (U/min)	10.86±0.16^{a}	8.84±0.05^{d}	8.15±0.02^{c}	8.41±0.04^{c}	9.31±0.11^{b}
	GSH (mg/dl)	6.88±0.13^{a}	3.06±0.03^{c}	4.19±0.01^{b}	4.51±0.02^{b}	6.71±0.17^{a}

*Means that do not share a letter are significantly different.

the CYP-treated group (AST: 108.25 U/L; ALP: 77.81 U/L; ALT: 67.66 U/L; Cholesterol: 92.17 mg/dL) (Table II). The CYP-treated group also exhibited significantly elevated levels of creatinine (0.86 mg/dL) and uric acid (19.64 mg/dL) compared to the control group (creatinine: 0.52 mg/dL; uric acid: 3.46 mg/dL). Post-treatment with CYP+AA, CYP+Se, and CYP+AA+Se led to a reduction in creatinine levels to 0.71 mg/dL, 0.74 mg/dL, and 0.60 mg/dL, respectively, when compared to the CYP-treated group (Table II).

Oxidative stress impacts

Analysis of variance in female albino rats revealed a significant reduction in the levels of CAT (1.83 U/min), SOD (3.70 U/min), POD (8.84 U/min), and GSH (3.06 mg/dL) in the CYP-treated group compared to the control group (CAT: 2.75 U/min; SOD: 6.86 U/min; POD: 10.86 U/min; GSH: 6.88 mg/dL). The group treated with CYP+AA+Se exhibited a significant difference in these antioxidant parameters compared to the control group. Furthermore, within the treatment groups, rats administered CYP+AA and CYP+Se showed a significant difference in these parameters when compared to the cypermethrin-treated group (Table III).

Analysis of variance in male albino rats also revealed a significant reduction in the levels of CAT (1.83 U/min),

SOD (3.70 U/min), POD (7.40 U/min), and GSH (3.08 mg/dL) in the CYP-treated group compared to the control group (CAT: 2.72 U/min; SOD: 6.91 U/min; POD: 10.8 U/min; GSH: 6.89 mg/dL). The group treated with CYP+AA+Se exhibited a significant difference in these antioxidant parameters compared to the control group. Furthermore, within the treatment groups, rats administered CYP+AA and CYP+Se showed a significant difference in these parameters when compared to the cypermethrin-treated group (Table III).

Histological alterations

Brain

Histopathological examination of the cerebral cortex in the control group revealed normal cytoarchitecture with well-defined, rounded neuronal cells (n) (Fig. 1A). In contrast, the male CYP-treated group exhibited neuronal cell necrosis (nc) and focal gliosis (g) (Fig. 1B). The female CYP-treated group displayed focal demyelination (d)of nerve fibers, hemorrhages (hm), and focal gliosis (g) (Fig. 1B). Male rats post-treated with CYP+AA showed neuronal cell necrosis (nc), while the CYP+Se group presented with neuronal cell degeneration (nd) (Fig. 1C, D). In female rats, post-treatment with CYP+AA and CYP+Se resulted in hemorrhage (hm) in the neocortex, broadened gaps (b) around veins, and focal hyperplasia (hp) of cerebral gliocytes (Fig. 2C, D). Notably, the female CYP+AA+Se treated group showed only slight focal hyperplasia (hp), indicating a potential protective effect conferred by the combined antioxidant administration (Fig. 2E).

Lungs

Histological examination of pulmonary tissue from control rats revealed normal lung architecture, characterized by intact bronchioles, alveolar sacs, alveolar ducts, alveoli, and pneumocytes. In contrast, male rats exposed to CYP exhibited focal inflammatory cell infiltration (i) and non-caseating granulomas containing multinucleated giant cells (gt) (Fig. 3B). Female rats treated with CYP showed hemorrhages (hm) and focal to diffuse thickening of the alveolar epithelial walls (t) (Fig. 4B). The group post-treated with the combination of ascorbic acid and selenium (CYP+AA+Se) displayed only slight diffuse thickening of the alveolar epithelial walls (t), suggesting a protective effect against CYP-induced alterations (Fig. 3E). However, female rats in the CYP+AA+Se group exhibited acidophilic infiltration (ai) of granulocytes surrounding arterioles (Fig. 4E).

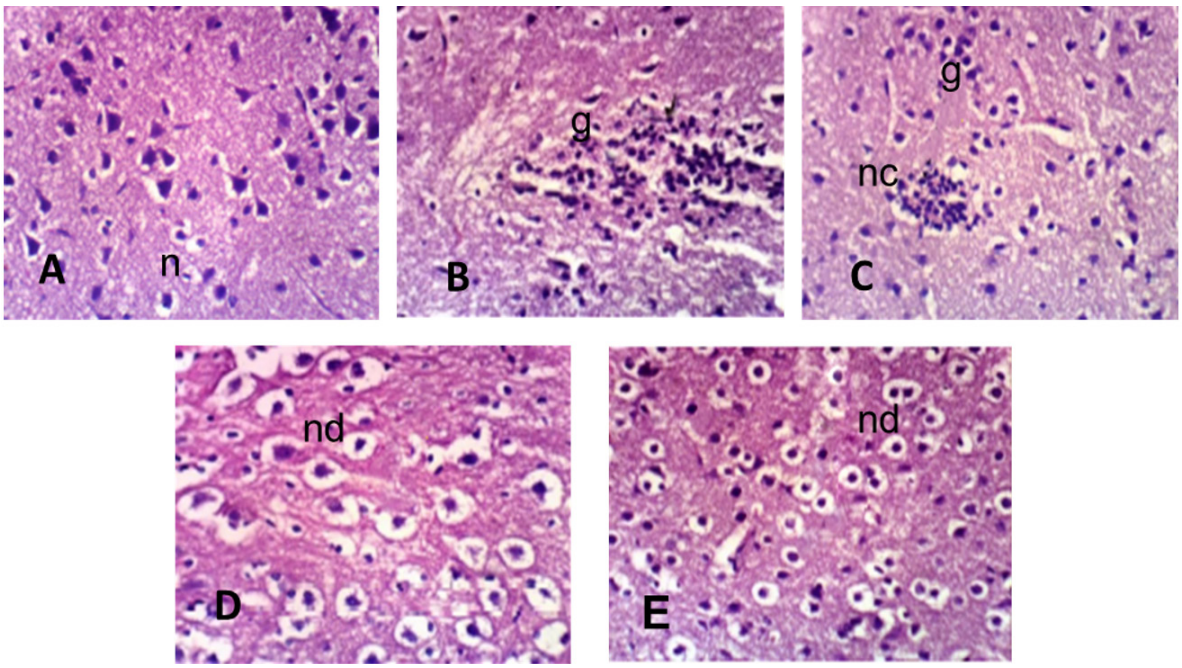

Fig. 1. Brain section of male albino rats (A) control group shows normal morphology of cerebral cortex with normal rounded neuronal cells (n) (B) group treated with cypermethrin showed neuronal cell necrosis (nc), focal gliosis (g) (C) group treated with CYP+AA showed neuronal cell necrosis (nc) (D) group treated with CYP+Se showed neuronal cell degeneration (nd) were observed (E) the group with protective effect of ascorbic acid with selenium against cypermethrin shows almost no histopathological alterations.

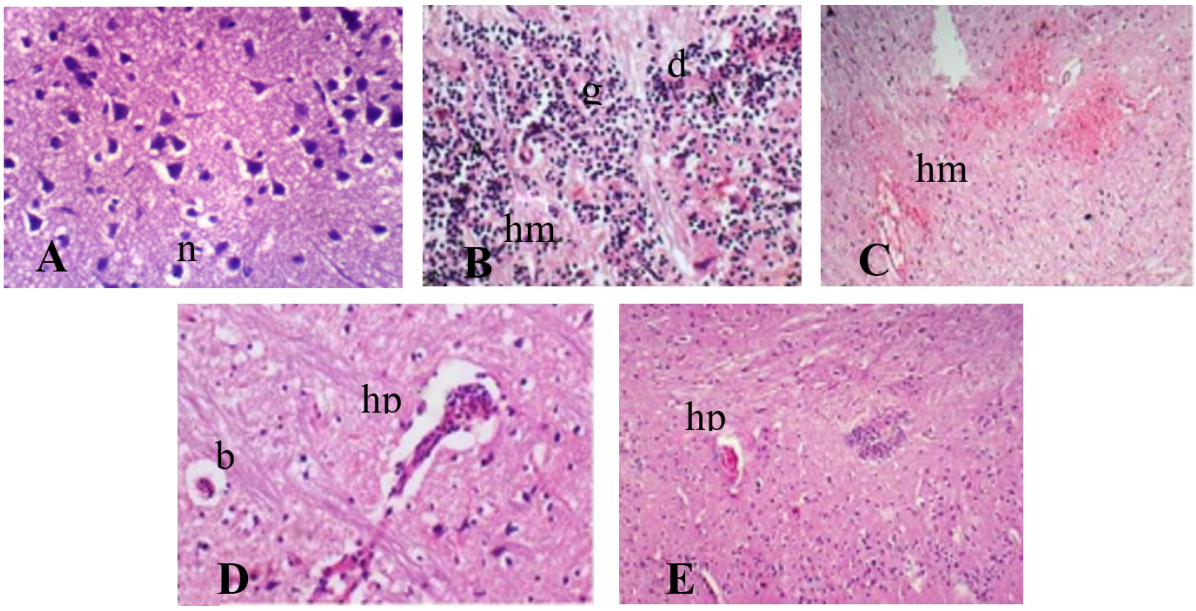

Fig. 2. Brain section of female albino rats (A) the control group shows normal morphology of cerebral cortex with normal rounded neuronal cells (n) (B) the group treated with cypermethrin shows focal demyelination (d) of nerve fibers, hemorrhages (hm), focal gliosis (g) (C) the group treated with CYP+ AA shows hemorrhage (hm) in neocortex (D) group treated with CYP+Se shows broadened gap (b) around veins, focal hyperplasia (hp) of cerebral gliocytes (E) the group shows slight focal hyperplasia (hp) with protective effect of ascorbic acid + selenium.

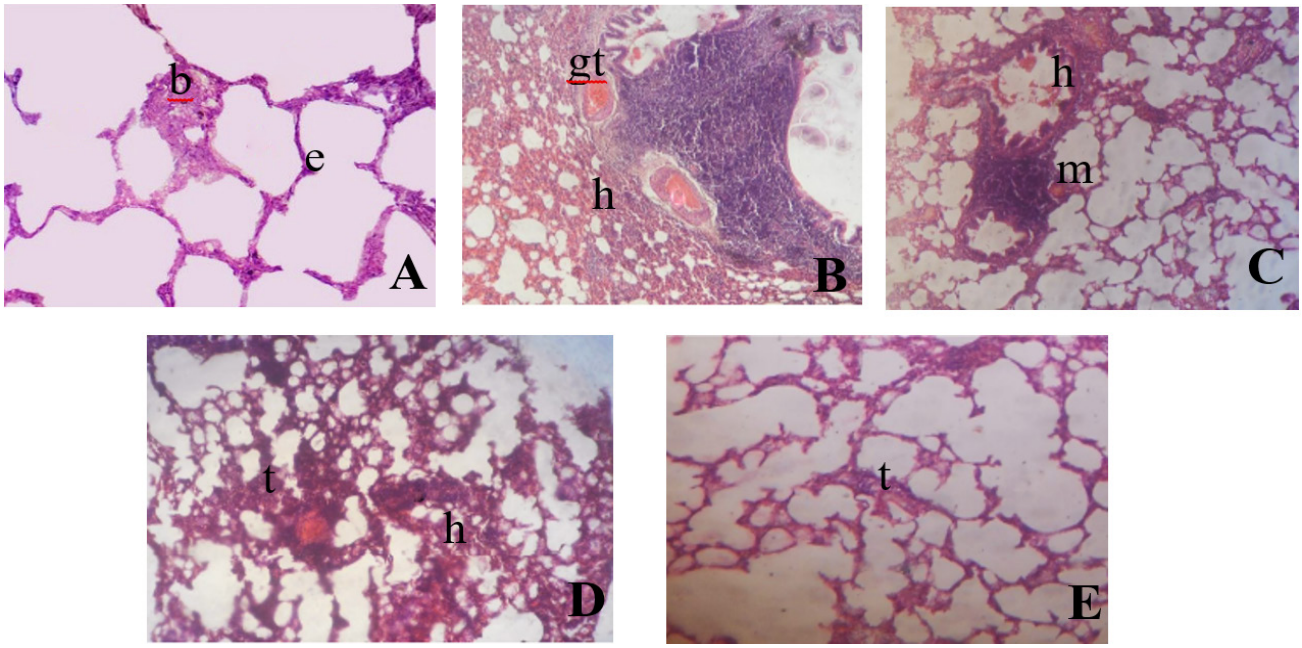

Fig. 3. Lung section of male albino rat (A) the control group shows pulmonary parenchyma with normal bronchiolar epithelium (br) and normal epithelial wall (e) (B) group treated with cypermethrin shows haemorrhages (h), focal infiltration (i), non-caseating granuloma with presence of giant cells (gt) (C) the group treated with CYP+AA shows haemorrhages (h), intraluminal aggregation of mucous materials (m) mixed with desquamated epithelium (D) the group treated with CYP+ Se shows haemorrhages (h), focal or diffuse thickened epithelial walls (t) of pulmonary alveolus (E) group with protective effect of ascorbic acid with selenium against cypermethrin shows slightly diffuse thickened epithelial walls (t) of pulmonary alveolus.

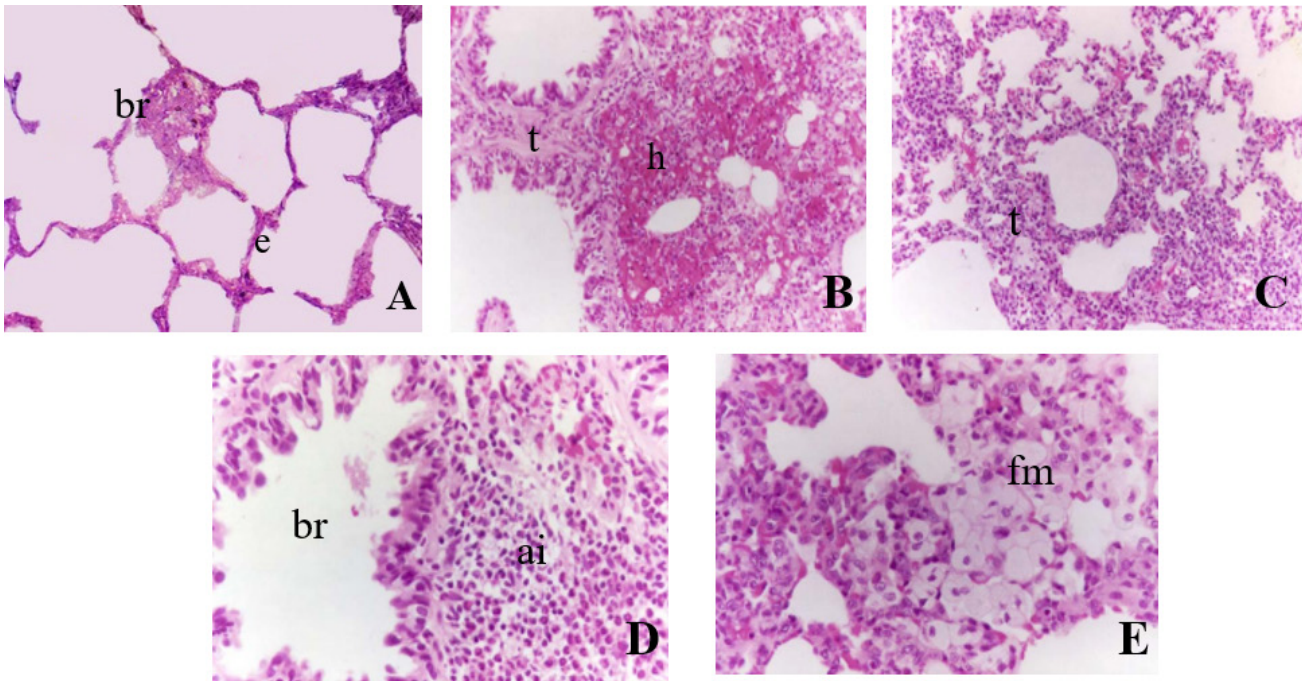

Fig. 4. Lung section of female albino rat (A) control group shows pulmonary parenchyma with normal bronchiolar epithelium (br) and normal epithelial wall (e) (B) group treated with cypermethrin shows haemorrhages (h), focal or diffuse thickened epithelial walls (t) of pulmonary alveolus (C) the group treated with CYP+AA shows abnormal distribution of cellular elements, thickened epithelial walls (t) of pulmonary alveolus (D) the group treated with CYP+ Se shows marked dilatation in bronchioles, slightly damaged the parenchyma of lungs (E) group with protective effect of ascorbic acid with selenium against cypermethrin shows acidophilia infiltration (ai) of granulocytes around arterioles.

DISCUSSION

Pyrethroid accumulation in tissues has been associated with the generation of ROS, leading to oxidative stress and contributing to the enhanced toxicity of these compounds by impairing tissue function (Khan *et al*., 2018). In the present study, administration of CYP at a dose of 30 mg/kg body weight resulted in a significant reduction ($P < 0.05$) in body weight gain in both male and female rats compared to the control group (Table I). These findings are consistent with previous studies reporting significantly reduced body weight gain in CYP-treated rats after 2 and 4 weeks of exposure (Hussien *et al*., 2013; Shuklan *et al*., 2023). The decline in body weight may be attributed to CYP's effecton the gastrointestinal tract, leading to reduced appetite and nutrient absorption (Mossa *et al*., 2015; Sankar *et al*., 2012), or may result from its direct systemic toxicity. Mahat *et al*. (2020) also suggested that the loss of lipids, proteins, and other essential macromolecules could contribute to the observed body mass reduction, indicating the severity of cypermethrin-induced toxicity (Mahat *et al*., 2020). Similarly, Desai *et al*. (2015) proposed that weight loss could stem from either the direct cytotoxic effects of pesticides on somatic cells or their indirect interference with central nervous system functions that regulate appetite, fluid balance, and endocrine activity (Desai *et al*., 2015). Interestingly, no significant changes were observed in the absolute or relative weights of the brain and lungs in CYP-treated rats of either sex compared to controls. This observation aligns with findings by Sangha *et al*. (2011), who reported non-significant alterations in the weights of vital organs, including the heart and lungs, following 2 and 4 weeks of CYP exposure.

The biochemical analysis revealed a significant increase in serum levels of AST, ALT, ALP, cholesterol, creatinine, and uric acid in cypermethrin (CYP)-treated rats compared to the control group (Table II), consistent with previous studies (Oladele *et al*., 2020; Abdou *et al*., 2012; Yavasoglu *et al*., 2006). Co-administration of selenium and ascorbic acid alongside CYP exhibited a protective effect, significantly improving the tested biochemical parameters relative to the CYP-only group (Elblehi *et al*., 2015; Ali *et al*., 2020). The elevation in serum AST, ALT, and ALP levels may reflect hepatic dysfunction, potentially resulting from hepatocellular damage or altered membrane permeability that disrupts

enzyme regulation (Mossa *et al*., 2015; Sankar *et al*., 2012). These enzymatic alterations, as well as other changes in serum constituents observed in CYP-intoxicated rats, are indicative of systemic toxicity (Zalata *et al*., 2013). The increase in serum cholesterol levels could be attributed to cypermethrin-induced hepatic dysfunction, as supported by the concurrent rise in AST and ALP, possibly due to increased membrane permeability or impaired lipid metabolism (Yousef *et al*., 2006). Additionally, CYP is known to affect neurotransmitter levels such as GABA and dopamine, which have been associated with elevated AST levels (Elblehi *et al*., 2015; Singh *et al*., 2015). Hepatic necrosis or acute liver injury may further explain the marked increase in AST, particularly under severe toxic conditions (Amir and Amir, 2015). ALT, a more liver-specific enzyme, is often elevated due to hepatocellular damage caused by toxicants, drugs, or viral infections, with degenerative liver changes contributing to elevated serum ALT and AST in CYP-exposed rats (Nair *et al*., 2011; Mohafrash *et al*., 2021). In the present study, levels of antioxidant markers including GSH, CAT, SOD, and POD were significantly reduced in CYP-treated rats compared to controls, while co-treatment with ascorbic acid and selenium mitigated these reductions in both sexes (Table III), highlighting their protective role. These findings are consistent with reports showing that CYP significantly ($P < 0.05$) increases TBARS activity while reducing levels of GSH, and the activities of GST, GPx, CAT, and SOD, particularly in brain tissues following 30 days of exposure (Giray *et al*., 2001; Abdou *et al*., 2012; Hussien *et al*., 2013; Sharma *et al*., 2014; Mossa *et al*., 2015; Khan *et al*., 2018). The oxidative stress induced by CYP may lead to lipid peroxidation, damage to cellular structures, apoptosis, reduced total GSH levels, and DNA fragmentation (Shaikh and Sethi, 2020, 2021). Similarly, Afolabi *et al*. (2019) reported elevated oxidative stress markers and altered GSH activity in rats intoxicated with pyrethroids.

According to previous findings, cypermethrin-induced oxidative stress results in an increased level of GST in plasma, while its activity is reduced in tissue organs, suggesting a compartment-specific response to oxidative damage (Eraslan *et al*., 2008). CAT activity was also diminished following CYP exposure, likely due to the impaired generation of superoxide anions and ROS (Arafa *et al*., 2015). Elevated ROS production is a key contributor to oxidative stress and appears to drive the changes observed in SOD and CAT activities in red blood cells (RBCs) after pesticide exposure. The antioxidant defense mechanisms including the dismutation of superoxide (O_2^-) by SOD and the subsequent breakdown of hydrogen peroxide (H_2O_2) by CAT help mitigate oxidative damage (Khan *et al*., 2005).

A decrease in SOD activity may reflect its excessive utilization in response to high levels of superoxide radicals generated under oxidative stress conditions. Similarly, increased levels of hydrogen peroxide in tissues may be linked to a reduction in GSH activity, as GSH plays a central role in peroxide detoxification (Raina *et al*., 2010). In repeated short-term cypermethrin toxicity trials, serum levels of ALP, ALT, AST, lactate dehydrogenase (LDH), and glucose were elevated, whereas CAT and SOD activities, cytochrome P450 content, and glycogen stores were significantly reduced, indicating systemic toxicity and disrupted metabolic balance (Manna *et al*., 2004). The present findings demonstrate that CYP exposure induces significant histopathological alterations in brain architecture. Histological analysis of brain tissues from control animals revealed a normal organization of neurocyte nuclei, as well as intact structures in the hypothalamus, hippocampal layers, and cerebral cortex in both male and female albino rats. In contrast, CYP-treated rats exhibited marked neurotoxic and genotoxic effects, including vascular congestion and degenerative changes in neural tissue, indicating substantial brain damage (Sayim *et al*., 2005; Muthuviveganandavel *et al*., 2008; Nair *et al*., 2011). However, co-administration of selenium and ascorbic acid alongside CYP resulted in notable histological improvement. Specifically, brain sections from this group showed recovery of neurocyte nuclei and restoration of cerebral cortex integrity (Fig. 1E), highlighting the protective and ameliorative effects of these antioxidants against CYP-induced neurotoxicity.

Histological examination of lung tissues from control rats showed normal architecture with no observable alterations in the bronchioles, alveolar sacs, alveolar ducts, alveoli, or pneumocytes, consistent with previous reports (Evans and Cooke, 2009). The alveolar cells in the control group appeared thin, squamous, and flat, indicative of healthy pulmonary structure. In contrast, CYP-treated rats exhibited histopathological changes characterized by the presence of macrophages within the alveolar walls (Fig. 3B), with some migrating into the lumen. Additionally, clusters of cuboidal secretory cells were observed near the septal junctions, reflecting tissue response to toxic insult (Sheikh *et al*., 2014). Histological observations in rats post-treated with CYP + AA and CYP + selenium (Se) showed varying degrees of damage, including focal gliosis (g), neuronal cell necrosis (nc), hemorrhage (h), focal hyperplasia (Hp), and neuronal degeneration (nd) in brain tissue. Lung tissues also exhibited hemorrhages, along with focal or diffuse thickening of the alveolar epithelial walls (t). Notably, rats treated with a combination of CYP + AA + Se showed only mild histopathological alterations

in both sexes, indicating a potential synergistic protective effect. These findings are consistent with earlier studies reporting the ameliorative role of antioxidants against pesticide-induced tissue damage (Afifi and Embaby, 2016; Al-Omar *et al*., 2020).

CONCLUSION

CYP exposure induced significant oxidative stress and histopathological damage in the lungs and brain tissues of adult albino rats. The toxicity was evidenced by increased lipid peroxidation, marked inhibition of antioxidant enzymes (SOD, CAT, POD, and GSH), and significant alterations in biochemical markers including ALP, AST, ALT, urea, uric acid, creatinine, and cholesterol. These findings highlight the potential health risks of CYP exposure, with implications for both animal and human health. Notably, treatment with ascorbic acid and selenium either individually or in combination exerted a protective effect by mitigating oxidative stress and supporting the recovery of normal histological and biochemical profiles. The combination therapy demonstrated the most pronounced ameliorative impact, suggesting a synergistic antioxidant role. These preliminary results support the therapeutic potential of ascorbic acid and selenium in counteracting CYP-induced toxicity and underscore the need for further studies to explore their application in clinical or environmental health contexts.

DECLARATIONS

Acknowledgement

We sincerely appreciate the constructive insights and continuous support of our colleagues throughout the completion of this study.

Funding

The study received no external funding.

IRB approval and ethical statement

The study was conducted in compliance with the ethical standards of Institutional bioethics committee (IBC), University of Agriculture, Faisalabad, Pakistan (D. No. 3742/ ORIC UAF, dated 10 December 2023). Thestudy was compiled with all the relevant legislations and experimental research was approved by the IBC on 10 December 2023.

Availability of data and material

The data used and analyzed during this project are available from the corresponding authors on reasonable request.

Generative AI and AI-assisted technology statement

The authors declare that no generative AI and AI assisted technology was used in the creation of this manuscript.

Statement of conflict of interest

The authors have declared no conflict of interest.

REFERENCES

Abd-El-Hameed, A.M. and Mahmoud, H.S., 2020. Cypermethrin induced apoptosis and testicular toxicity by upregulation of p53 in the brain and testis of male rats is alleviated by Sesame oil. *J. Taibah Univ. Sci*., **14**: 1342–1349. https://doi.org/10.1080/16583655.2020.1822057

Abdou, H.M., Hussien, H.M. and Yousef, M.I., 2012. Deleterious effects of cypermethrin on rat liver and kidney: Protective role of sesame oil. *J. environ. Sci. Hlth. B*, **47**: 306–314. https://doi.org/10.1080/03601234.2012.640913

Afifi, O.K. and Embaby, A.S., 2016. Histological study on the protective role of ascorbic acid on cadmium induced cerebral cortical neurotoxicity in adult male albino rats. *J. Microsc. Ultrastruct*, **4**: 36–45. https://doi.org/10.1016/j.jmau.2015.10.001

Afolabi, O.K., Aderibigbe, F.A., Folarin, D.T., Arinola, A. and Wusu, A.D., 2019. Oxidative stress and inflammation following sub-lethal oral exposure of cypermethrin in rats: Mitigating potential of epicatechin. *Heliyon*, **5**. https://doi.org/10.1016/j.heliyon.2019.e02274

Ali, H.F.H., El-Sayed, N.M., Ahmed, A.A., Hanna, P.A. and Moustafa, Y.M., 2020. Nano selenium ameliorates oxidative stress and inflammatory response associated with cypermethrin-induced neurotoxicity in rats. *Ecotoxicol. environ. Saf*., **195**: 110479. https://doi.org/10.1016/j.ecoenv.2020.110479

Al-Omar, M.S., Naz, M., Mohammed, S.A., Mansha, M., Ansari, M.N., Rehman, N.U. and Khan, R.A., 2020. Pyrethroid-induced organ toxicity and anti-oxidant-supplemented amelioration of toxicity and organ damage: The protective roles of ascorbic acid and α-tocopherol. *Int. J. environ. Res. Publ. Hlth*., **17**: 6177. https://doi.org/10.3390/ijerph17176177

Amir, N. and Amir, N., 2015. The effect of cypermethrin on Jambal Roti to AST and ALT levels the Wistar Rat (*Rattus norvegicus*). *Int. J. PharmTech Res.,* **8**: 235-240.

Arafa, M.H., Mohamed, D.A. and Atteia, H.H., 2015. Ameliorative effect of N-acetyl cysteine on alpha-

cypermethrin-induced pulmonary toxicity in male rats. *Environ. Toxicol.*, **30**: 26–43. https://doi.org/10.1002/tox.21891

Baghcheghi, Y., Razazpour, F., Seyedi, F., Arefinia, N. and Hedayati-Moghadam, M., 2024. Exploring the molecular mechanisms of PPARγ agonists in modulating memory impairment in neurodegenerative disorders. *Mol. Biol. Rep.*, **51**: 945. https://doi.org/10.1007/s11033-024-09850-6

Bancroft, J.D. and Gamble, M., 2008. *Theory and practice of histological techniques*. Elsevier Health Sciences.

Desai, K.R., Moid, N., Patel, P.B. and Highland, H.N., 2015. Protective efficacy of *Allium sativum* on deltamethrin induced toxicity in reproductive tissues of male mice. *Int. J. Pharm. Sci. Res.*, **6**: 1711.

Doseděl, M., Jirkovský, E., Macáková, K., Krčmová, L.K., Javorská, L., Pourová, J. and Oemonom, 2021. Vitamin C sources, physiological role, kinetics, deficiency, use, toxicity, and determination. *Nutrients*, **13**: 615. https://doi.org/10.3390/nu13020615

Elblehi, S.S., Oda, S.S., Tohamy, H.G. and Elmanakhly, E.S.M., 2015. Protective effect of vitamin E and selenium combination on cypermethrin-induced toxicity in male rats. *Alex. J. Vet. Sci.*, **47**. https://doi.org/10.5455/ajvs.203149

Eraslan, G., Kanbur, M., Silici, S., Altinordulu, S. and Karabacak, M., 2008. Effecs of cypermethrin on some biochemical changes in rats: The protective role of propolis. *Exp. Anim.*, **57**: 453–460. https://doi.org/10.1538/expanim.57.453

Erkan, M., Aydin, Y., Yilmaz, B.O. and Yildizbayrak, N., 2021. Protective effects of vitamin C against fluoride toxicity. *Toxicology*, pp. 435–445. https://doi.org/10.1016/B978-0-12-819092-0.00043-1

Evans, M.D. and Cooke, M.S., 2009. *Oxidative damage to nucleic acids*. Springer Science and Business Media.

Giray, B., Gürbay, A. and Hincal, F., 2001. Cypermethrin-induced oxidative stress in rat brain and liver is prevented by Vitamin E or allopurinol. *Toxicol. Lett.*, 118: 139–146. https://doi.org/10.1016/S0378-4274(00)00277-0

Gündüz, A., Yalçın, E. and Çavuşoğlu, K., 2021. Combined toxic effects of aflatoxin B2 and the protective role of resveratrol in Swiss albino mice. *Sci. Rep.*, **11**: 1–14. https://doi.org/10.1038/s41598-021-95879-7

Hao, F., Bu, Y., Huang, S., Li, W., Feng, H. and Wang, Y., 2023. Effects of pyrethroids on the cerebellum and related mechanisms: A narrative review. *Crit. Rev. Toxicol.*, **53**: 229–243. https://doi.org/10.1080/10408444.2023.2229384

Hussien, H.M., Abdou, H.M. and Yousef, M.I., 2013. Cypermethrin induced damage in genomic DNA and histopathological changes in brain and haematotoxicity in rats: the protective effect of sesame oil. *Brain Res. Bull.*, **92**: 76–83. https://doi.org/10.1016/j.brainresbull.2011.10.020

Joshi, S.C., Bansal, B. and Jasuja, N.D., 2011. Evaluation of reproductive and developmental toxicity of cypermethrin in male albino rats. *Toxicol. Environ. Chem.*, **93**: 593–602. https://doi.org/10.1080/02772248.2010.537441

Kašuba, V., Tariba, L.B., Lucić, V.A., Katić, A., Kopjar, N., Micek, V. and Žunec, S., 2022. Evaluation of toxic effects induced by sub-acute exposure to low doses of α-cypermethrin in adult male rats. *Toxics*, **10**: 717. https://doi.org/10.3390/toxics10120717

Khan, A.M., Raina, R., Dubey, N. and Verma, P.K., 2018. Effect of deltamethrin and fluoride co-exposure on the brain antioxidant status and cholinesterase activity in Wistar rats. *Drug Chem. Toxicol.*, **41**: 123–127. https://doi.org/10.1080/01480545.2017.1321009

Khan, B.A., Nadeem, M.A., Nawaz, H., Amin, M.M., Abbasi, G.H., Nadeem, M. and Ayub, M.A., 2023. Pesticides: Impacts on agriculture productivity, environment, and management strategies. In: *Emerging contaminants and plants: Interactions, adaptations and remediation technologies*. Springer, pp. 109–134. https://doi.org/10.1007/978-3-031-22269-6_5

Khan, S.M., Sobti, R.C. and Kataria, L., 2005. Pesticide-induced alteration in mice hepato-oxidative status and protective effects of black tea extract. *Clin. Chim. Acta*, **358**: 131–138. https://doi.org/10.1016/j.cccn.2005.02.015

Kuban, W. and Daniel, W.A., 2021. Cytochrome P450 expression and regulation in the brain. *Drug Metab. Rev.*, **53**: 1–29. https://doi.org/10.1080/03602532.2020.1858856

Mahat, S., Jha, C.B., Shrestha, S. and Koirala, S., 2020. Effect of vitamin E on cypermethrin induced toxicity in cerebrum of wistar albino rats: A histological study. *J. Karnali Acad. Hlth. Sci.*, **3**: 1–12. https://doi.org/10.3126/jkahs.v3i1.28457

Manna, S., Bhattacharyya, D., Basak, D.K. and Mandal, T.K., 2004. Single oral dose toxicity study of a-cypermethrin in rats. *Indian J. Pharmacol.*, **36**: 25.

Matić, M.M., Paunović, M.G., Milošević, M.D.,

Ognjanović, B.I. and Saičić, Z.S., 2021. Hematoprotective effects and antioxidant properties of β-glucan and vitamin C against acetaminophen-induced toxicity: An experimental study in rats. *Drug Chem. Toxicol.*, **44**: 302–309. https://doi.org/10.1080/01480545.2019.1587451

Mohafrash, S.M.M., Hassan, E.E., El-Shaer, N.H. and Mossa, A.T.H., 2021. Detoxification gene expression, genotoxicity, and hepatorenal damage induced by subacute exposure to the new pyrethroid, imiprothrin, in rats. *Environ. Sci. Pollut. Res.*, **28**: 33505–33521. https://doi.org/10.1007/s11356-021-13044-z

Mossa, A.T.H., Heikal, T.M., Belaiba, M., Raoelison, E.G., Ferhout, H. and Bouajila, J., 2015. Antioxidant activity and hepatoprotective potential of *Cedrelopsis grevei* on cypermethrin induced oxidative stress and liver damage in male mice. *BMC Complement. Altern. Med.*, **15**: 1–10. https://doi.org/10.1186/s12906-015-0740-2

Muthuviveganandavel, V., Muthuraman, P., Muthu, S. and Srikumar, K. 2008. A study on low dose cypermethrin induced histopathology, lipid peroxidation and marker enzyme changes in male rat. *Pestic Biochem. Physiol.*, **91**: 12–16. https://doi.org/10.1016/j.pestbp.2007.11.010

Nair, R.R., Abraham, M.J., Lalithakunjamma, C.R., Nair, N.D. and Aravindakshan, C.M., 2011. A pathomorphological study of the sublethal toxicity of cypermethrin in Sprague Dawley rats. *Int. J. Nutr. Pharmacol. Neurol. Dis.,* **1**: 179. https://doi.org/10.4103/2231-0738.84211

Namdev, N., Rai, G. and Mahobiya, P., 2023. Protective role of ashwagandha and quercetin over cypermethrin induced hypothyroidism: A hematological study in mice. *Adv. Zool. Bot.*, **11**: 103–111. https://doi.org/10.13189/azb.2023.110202

Oda, S.S. and El-Maddawy, Z.K., 2012. Protective effect of vitamin E and selenium combination on deltamethrin-induced reproductive toxicity in male rats. *Exp. Toxicol. Pathol.*, **64**: 813–819. https://doi.org/10.1016/j.etp.2011.03.001

Oladele, J., Adewale, O., Oyewole, O., Gbolagbade, A. and Oyeleke, M., 2020. Assessment of the protective effects of vitamin C and E on cypermethrin-induced nephrotoxicity and electrolyte imbalance in wistar rats. *J. Basic appl. Res. Biomed.*, **6**: 1–6. https://doi.org/10.51152/jbarbiomed.v6i1.1

Oshatunberu, M.A., Oladimeji, A., Sawyerr, O.H. and Raimi, M.O., 2023. Search what you can't see-evaluation pestic residues grain sold sel mark. *S. Niger. Curr. Res. Publ. Hlth.*, **3**: 10–36. https://doi.org/10.31586/crph.2023.566

Raina, R., Verma, P.K., Pankaj, N.K., Kant, V. and Prawez, S., 2010. Protective role of L-ascorbic acid against cypermethrin-induced oxidative stress and lipid peroxidation in Wistar rats. *Toxicol. environ. Chem.*, **92**: 947–953. https://doi.org/10.1080/02772240903174781

Rashid, U., Qureshi, I.Z., Jan, S., Khalid, T. and Khan, D.A., 2023. Protective effects of selenium against cypermethrin induced hepatorenal damage in Sprague Dawley rats. *World J. Biol. Pharm. Hlth. Sci.*, **22**: 284–298. https://doi.org/10.30574/wjbphs.2023.13.1.0293

Sangha, G.K., Kaur, K. and Khera, K.S., 2013. Cypermethrin induced pathological and biochemical changes in reproductive organs of female rats. *J. environ. Biol.*, **34**: 99.

Sangha, G.K., Kaur, K., Khera, K.S. and Singh, B., 2011. Toxicological effects of cypermethrin on female albino rats. *Toxicol. Int.*, **18**: 5. https://doi.org/10.4103/0971-6580.75844

Sankar, P., Telang, A.G. and Manimaran, A., 2012. Protective effect of curcumin on cypermethrin-induced oxidative stress in Wistar rats. *Exp. Toxicol. Pathol.*, **64**: 487–493. https://doi.org/10.1016/j.etp.2010.11.003

Sayim, F., Yavasoglu, N.Ü.K., Uyanikgil, Y., Aktug, H., Yavasoglu, A. and Turgut, M., 2005. Neurotoxic effects of cypermethrin in Wistar rats: A haematological, biochemical and histopathological study. *J. Hlth. Sci.*, **51**: 300–307. https://doi.org/10.1248/jhs.51.300

Shaikh, N.I. and Sethi, R.S., 2020. Exposure to chlorpyrifos and cypermethrin alone or in combination induces developmental abnormalities and lung damage in animal models: A review. *J. Ent. Zool. Stud.*, **8**: 1923–1928. https://doi.org/10.22271/j.ento.2020.v8.i5aa.7769

Shaikh, N.I. and Sethi, R.S., 2021. Differential gene expression profile of mice lung following chronic dietary exposure to chlorpyrifos and/or cypermethrin. *J. Hum. Reprod. Sci.,* **7**: 99. https://doi.org/10.22271/j.ento.2021.v9.i1b.8139

Sharma, P., Huq, A.U. and Singh, R., 2014. Cypermethrin-induced reproductive toxicity in the rat is prevented by resveratrol. *J. Hum. Reprod. Sci.*, **7**: 99. https://doi.org/10.4103/0974-1208.138867

Sheikh, N., Javed, S., Asmatullah, A., Ahmad, K.R., Abbas, T. and Iqbal, J., 2014. Histological changes in the lung and liver tissues in mice exposed to pyrethroid inhalation. *Walailak J. Sci. Technol.*, **11**:

843–849.

Shilpakar, O. and Karki, B., 2021. Cypermethrin poisoning manifesting with prolonged bradycardia: A case report. *Toxicol. Rep.*, **8**: 10–12. https://doi.org/10.1016/j.toxrep.2020.12.005

Shuklan, P., Raj, A., Chauhan, K., Madan, P. and Rani, S., 2023. Systematic toxicity of cypermethrin and alterations in behavior of albino rats. *ACS Omega*, **8**: 14766–14773. https://doi.org/10.1021/acsomega.3c00817

Singh, A., Mudawal, A., Shukla, R.K., Yadav, S., Khanna, V.K., Sethumadhavan, R. and Parmar, D., 2015. Effect of gestational exposure of cypermethrin on postnatal development of brain cytochrome P450 2D1 and 3A1 and neurotransmitter receptors. *Mol. Neurobiol.*, **52**: 741–756. https://doi.org/10.1007/s12035-014-8903-6

Tongjai, P., Hongsibsong, S. and Sapbamrer, R., 2021. *Open access research article*.

Yavasoglu, A., Sayim, F., Uyanikgil, Y., Turgut, M. and Karabay-Yavasoglu, N.Ü., 2006. The pyrethroid cypermethrin-induced biochemical and histological alterations in rat liver. *J. Hlth. Sci.*, **52**: 774–780. https://doi.org/10.1248/jhs.52.774

Yousef, M.I., Awad, T.I. and Mohamed, E.H., 2006. Deltamethrin-induced oxidative damage and biochemical alterations in rat and its attenuation by Vitamin E. *Toxicology*, **227**: 240–247. https://doi.org/10.1016/j.tox.2006.08.008

Yüksel, Y., Aslan, E., Tosun, M., Altunbaş, K., Akkaya, Ö.Ö., Demirel, H.H. and Pektaş, M.B., 2023. Protective effects of resveratrol on permethrin-induced fetotoxicity in rats. *Anatol. J. Bot.*, **7**: 21–28. https://doi.org/10.30616/ajb.1241886

Zalata, A., Atwa, A., Badawy, A.E-N., Aziz, A., El-Baz, R., Elhanbly, S. and Mostafa, T., 2013. Tumor necrosis factor-α gene polymorphism relationship to seminal variables in infertile men. *Urology*, **81**: 962–966. https://doi.org/10.1016/j.urology.2013.01.026

Ziada, R.M., Nahas, A.A., Farag, A. and Kotb, G.A., 2020. Protective efficacy of combined administration of vitamins c and curcumin on cypermethrin-induced oxidative stress in male albino rats. *Egypt. Acad. J. biol. Sci. F Toxicol. Pest Contr.*, **12**: 109–118. https://doi.org/10.21608/eajbsf.2020.113976

Zuo, M., Ye, M., Lin, H., Liao, S., Xing, X., Liu, J. and Ren, X., 2024. Mitochondrial dysfunction in environmental toxicology: Mechanisms, impacts, and health implications. *Chem. Res. Toxicol.*, **37**: 1794–1806. https://doi.org/10.1021/acs.chemrestox.4c00328